

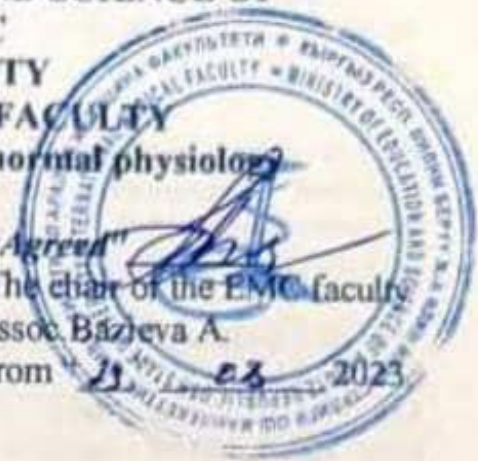


THE MINISTRY OF EDUCATION AND SCIENCE OF
KYRGYZ REPUBLIC
OSH STATE UNIVERSITY
INTERNATIONAL MEDICAL FACULTY

Department of anatomy, histology and normal physiology

«Approved» 
at faculty meeting, protocol № 1
from "29" 08 2023.
Head of depart, assoc. S. Dzh. Dzholdubaev

«Agreed» 
The chair of the EMC faculty
assoc. Bazyeva A.
from "29" 08 2023



SYLLABUS

(3-semester 2023-2024 academic year)

discipline: Topographic anatomy and Operative surgery

for students studying in the direction:

"560001-General Medicine (GM)"

Form of study: full-time

Total credits - 5

Course - 2

Semester - 3

Total labor input - 150 hours

Classrooms - 75 hours (lectures - 30 hours, practical classes - 45 hours)

CPC - 75 hours

The number of frontier controls (FK) - 2

Exam - 3 semester

Information of teachers:

Dzholdubaev Sagynbek Dzharkynbaevich, associate Professor Department of anatomy, histology and normal physiology, room №105

Contact information: working hours 8 00 - 17 00

mob. tel: +996 777003666, +996 559 921029

Mirlan Nuruev, senior teacher of department of anatomy, histology and normal physiology, , room № 204

Contact information:

working hours mob.: +996 773 928729, +996 559 727775

E-mail: nuruev1976@mail.ru

Date: 2023-2024-academic year

1. The purpose of the discipline: Formation of knowledge of clinical, anatomical and surgical training of students, necessary for continuing education at clinical departments and further professional activity.

2. Learning outcomes (LO) and student competencies formed in the course of studying the discipline "**Topographic anatomy and operative surgery**". In the process of mastering the discipline, the student will achieve the following learning outcomes (LO) and will have the appropriate competencies:

LO BEP code and its wording	Competencies BEP	LO discipline code (LOd) and its wording
<p>LO₁ – Able to use basic knowledge of humanities, natural sciences, economics in professional work</p>	<p>BK-1 - able to analyze socially significant problems and processes, to use in practice the methods of the humanities, natural sciences, biomedical and clinical sciences in various types of professional and social activities;</p>	<p>Knows and understands:</p> <ul style="list-style-type: none"> • methods of human body research; <p>Can:</p> <ul style="list-style-type: none"> • dissect the human body; • use basic knowledge in the analysis and description of the dissected human body;
<p>LO₅ – Able to assess morphofunctional, physiological conditions and pathological processes and apply research methods of sick adults and children to solve professional problems</p>	<p>PK-4 - able to apply methods of asepsis and antiseptics, use medical instruments, master the technique of caring for sick adults and children;</p>	<p>Knows and understands:</p> <ul style="list-style-type: none"> • primary surgical treatment of wounds; safety regulations and work in physical, chemical, biological laboratories, with reagents, devices, animals; • apply methods of asepsis and antiseptics, master the technique of caring for sick adults and children; <p>Can:</p> <ul style="list-style-type: none"> • use general and some special surgical instruments;
<p>LO₇ – Is able to apply basic knowledge in the field of diagnostic activity to solve professional tasks</p>	<p>PK-11 – capable and ready to make a diagnosis based on the results of biochemical and clinical studies, taking into account the course of pathology in organs, systems and the body as a whole;</p> <p>PK-12 - able to analyze the patterns of functioning of individual organs and systems, use knowledge of anatomical and physiological features, basic methods of clinical and laboratory examination and assessment of the functional state of the body of an adult and children, for timely diagnosis of diseases and pathological processes;</p>	<p>Knows and understands:</p> <ul style="list-style-type: none"> • the general principle of the layered structure of the human body; • topographic anatomy of specific areas and internal organs; • indications, techniques for performing simple emergency surgical interventions; • surgical instruments; <p>Can:</p> <ul style="list-style-type: none"> • palpate the main bone landmarks on a person, outline the topographic contours of organs and the main vascular and nerve trunks; • perform separate surgical techniques and operations on biological (educational) material; • layer-by-layer separation of soft tissues, tying knots, layer-by-layer suturing of wounds, removal of skin sutures;

In the course of mastering the discipline, the student must achieve the following **learning outcomes:**

Course Prerequisites

“At the entrance”, in accordance with the curriculum, the study of topographic anatomy is carried out in the third semester. Basic knowledge required to study the discipline

formed by:

- ✓ In the humanitarian cycle: Latin;
- ✓ In the cycle of natural-scientific, biomedical disciplines: biology; normal and clinical anatomy, histology, embryology, cytology; normal and pathological physiology.

Course post requisites

“At the exit”, the foundation is laid for students to study propaedeutics of clinical disciplines and the formation of skills to apply knowledge of human anatomy in the process of further study of all clinical disciplines and in future professional activities. Based on the requests and requirements of the clinical - internal diseases, surgical diseases, obstetrics and gynecology, etc., as well as medical and preventive disciplines, in the teaching of topographic anatomy special attention is paid to applied aspects.

Technological map of discipline

Name of disciplines Total hours	Name of disciplines Total hours	Name of disciplines Total hours	Name of disciplines Total hours	1 Module				2 Module				Final control
				Aud. hours		SW	Control	Aud. hours		SW	Control	
				lecture	Practice			Lecture	Practical			
	150	75	75	16	24	35	2	14	21	40	2	
Points:				30	30	30	30	30	30	30	30	
Total modules				30				30				Total modules 60

2.

DISCIPLINE PROGRAM

INTRODUCTION

The subject and tasks of topographic anatomy. The relationship of topographic anatomy with clinical disciplines. The value of the work of I.F. Bush, I.V. Buyalsky, N.I. Pirogova, A.A. Bobrova, P.I. Dyakonova, S.N. Delitsyna, V.N. Shevkunenko, N.N. Burdenko, P.A. Herzen, S.I. Spasokukotsky, A.N. Bakuleva, A.A. Vishnevsky and others in the formation and development of topographic anatomy and surgical surgery. Further development of the domestic school of topographic anatomy and operative surgery in the works of A.N. Maksimenkova, E.M. Margorina, G.I. Ostroverkhova, V.V. Kovanova, B.V. Ogneva Yu.F. Isakova, Yu.M. Lopukhin and other scientists.

COMMON PART

The basic concepts of topographic anatomy (the region and its boundaries, external and internal landmarks, the projection of anatomical formations on the skin integuments, their holotopia, skeletonotopia, syntopia, fascial sheaths, cellular spaces, collateral circulation, etc.).

A topographic and anatomical region is a part of the human body that is separated from adjacent areas by conventional or natural borders and has a structure different from other adjacent areas.

An external reference is a bone protrusion, a skin fold, muscle relief, or other formations that are constant for a given area.

A projection is a point, a line or a geometric figure, drawn taking into account the external landmarks of the area and corresponding to deeply located formations.

The doctrine of individual human anatomical variability (typical anatomy). Age-related structural features of the topography of organs and systems.

Methods of topographic anatomical studies on a living person (projection anatomy, fluoroscopy, radiography, computed tomography, ultrasound and other modern research methods); on a corpse (layered anatomical preparation, including with vessels injected with colored, radiopaque hardening masses, cuts of frozen corpses according to N.I. Pirogov, diaprography, corrosion preparations, etc.); plastination method.

The study of topographic and anatomical layers of each of the areas:

Skin (thickness, mobility, skin folds, the presence of sebaceous and sweat glands, innervation).

The projection of anatomical formations on the skin integument.

Subcutaneous tissue (severity, layers, blood vessels and nerves).

Superficial fascia (severity, structural features).

Own fascia (structural features, fascial and bone-fibrous vaginas, vaginas of the neurovascular bundles).

Muscles (groups, layers, intermuscular cellular prostates, grooves, canals).

Bones and joints (bone and joint structure weaknesses, synovial bags).

Vascular-neural bundles (topography, branches, anastomoses).

Cellular spaces: borders, communication.

Organs (holotopia, syntopia, skeletonotopy, blood supply and venous outflow, lymph drainage, sources of innervation).

SPECIAL PART

LIMBS

General characteristics of the upper and lower extremities in adults. Division by area. External landmarks and projections. Teaching N.I. Pirogov about vascular sheaths and case structure of limbs. Fascias, fascial beds and intermuscular partitions, cell spaces. The pathways of purulent sagging and hematomas along interfascial cell spaces. The system of deep and superficial veins, their relationship to the fascia. Collateral circulation. The system of deep and superficial lymphatic vessels and nodes. Zone of skin innervation.

UPPER LIMB

Subclavian region. Borders. External landmarks. Layers, fascia and cellular spaces. Neurovascular formations.

Deltoid region. Borders. External landmarks. Layers Fake fiber space. Vessels, nerves. Synovial bags. Shoulder joint. Its features in newborns. Joint bag and its strengthening device. Weak points of the joint capsule. The position of the head of the shoulder bag with dislocations in the shoulder joint.

Scapular region. Borders. External landmarks. Layers Bone fascial bed supraspinatus and infraspinatus fossa. Vessels and nerves.

Axillary region (axillary fossa). Borders. External reference points The projection of the axillary artery onto the skin. The walls of the axillary fossa. Topography of the axillary artery, its relationship with the axillary vein, bundles and nerves of the brachial plexus. The connection of the fiber of the axillary fossa with the cellular spaces of the shoulder, deltoid, scapular, subclavian and supraclavicular areas. Arterial collaterals in the shoulder joint.

Shoulder. Borders. External landmarks. Layers The front region of the shoulder: layers, fascial bed and its contents. Topography of neurovascular formations of the anterior region of the shoulder. The projection of the brachial artery. The posterior region of the shoulder: layers, fascial bed and its contents. Neurovascular formations. The position of fragments in a fracture of the humerus at various levels.

Elbow region. Borders. External landmarks. Anterior ulnar region: topography of superficial and deep neurovascular formations, lymph nodes. Rear ulnar region: layers, ulnar synovial bag.

Neurovascular formations. Elbow joint. Joint capsule, its weak points. Arterial collaterals in the elbow joint. The position of the bones with dislocations in the elbow joint.

Forearm. Borders. External landmarks. The front region of the forearm. Anterior fascial bed, muscle layers. Topography of neurovascular formations. Projection of the median and ulnar nerves, radial and ulnar arteries. Pirogov-Paron space, its connection with the cellular spaces of neighboring regions. The rear region of the forearm. Posterior and lateral fascial spaces, muscle layers. Neurovascular formations. The position of fragments in fractures of the forearm bones at various levels.

Brush. Borders. External landmarks. Wrist. Layers of the palmar and dorsal surfaces. Wrist channels and their contents. Neurovascular formations. Wrist joint.

Palmar surface of the hand and fingers. Projection of the superficial and deep arterial arches, motor branches of the median and ulnar nerves. Features of the structure of the skin, subcutaneous fat, palmar aponeurosis. Fascial palms of the palm. Cellular spaces of the palm and their connection with the cellular spaces of neighboring areas. Bone-fibrous canals, tendon apparatus, synovial sheaths of the flexor tendons of the hand, their structure and importance in the spread of inflammatory processes in the hand. Innervation of the skin and muscles of the palmar surface of the hand and fingers, surgical anatomy of syndactyly.

The back surface of the hand and fingers. Zone of skin innervation. Layers Vascular-neural formations of the back surface of the hand. Projections of the joint spaces of the metacarpophalangeal, interphalangeal joints and their ligamentous apparatus.

LOWER LIMB

Gluteal region. Borders. External landmarks. Layers Fascias, cellular spaces and their connection with the cellular spaces of neighboring areas. Neurovascular formations, their projection onto the skin. Hip joint. Joint capsule and its strengthening apparatus. Weak points of the joint capsule. The position of the femoral head with dislocations. The position of bone fragments in fractures of the femoral neck. Arterial collaterals in the hip area.

Hip. Borders. External landmarks. Inguinal ligament, vascular and muscle lacunae. Fascial beds, intermuscular septa, muscle groups.

Front thigh area. The femoral (scarp) triangle. Topography of neurovascular formations, their projection on the skin. Femoral canal, walls, openings. Femoral hernia. Obturator channel. The neurovascular bundle. The leading channel (Gunther channel).

The back of the thigh. Layers, fascial bed. Neurovascular formations. The sciatic nerve. The position of bone fragments in hip fractures at various levels.

Knee. Borders. External landmarks.

Anterior region of the knee. Layers Neurovascular formations, synovial bags.

The posterior region of the knee (popliteal fossa). Layers Fascias. The muscles. Topography of neurovascular formations, projection of the popliteal artery on the skin. Knee-joint. Joint bag. Strengthening apparatus of the joint. Weak points of the joint capsule. Synovial inversion of the joint capsule and their role in the spread of purulent streaks. Collateral circulation in the knee joint.

Shin. Borders. External landmarks.

Anterior region of tibia. Fascial beds. Topography of neurovascular formations. Projection on the skin of the anterior tibial artery.

Lateral region of the tibia. Layers Fascial bed. Upper muscular-fibular canal. Topography of neurovascular formations.

The back region of the leg. Layers Fascial beds. Ankle-popliteal and lower muscular-fibular canals.

The connection of the cellular spaces of the lower leg with the tissue of the popliteal fossa and foot.

Topography of the neurovascular formations of the lower leg. Projection of the posterior tibial artery. The position of fragments in fractures of the tibia and fibula at different levels.

Ankle joint areas. Borders. External landmarks. The area of the medial ankle. Layers Topography of the flexor tendons of the foot and neurovascular formation. Synovial vaginal tendons.

Front area. Layers Bone-fibrous canals. Topography of blood vessels, nerves, tendons.

The posterior region (region of the Achilles tendon), synovial bags, blood vessels, nerves.

Ankle joint. Joint capsule and its strengthening apparatus. Weaknesses of the articular bag. Blood supply, innervation. The position of bone fragments of the leg and foot in fractures of the ankles.

Foot. Borders. External landmarks.

The back area. Borders. Layers Fascias, muscles, tendons. Topography of neurovascular formations. Projection on the skin of the dorsal artery of the foot. Zone of skin innervation. Projection of the joints of Chopard, Lisfranc.

The sole area, layers, fascial beds. Topography of muscles, blood vessels, nerves. Cellular spaces, their connection with the tissue of the leg and the rear foot.

HEAD

Borders. External landmarks. Individual and age differences.

The brain part. Borders. Areas. Fronto-parieto-occipital and temporal areas. Layers, vessels, nerves. Cellular spaces and their connection with the fiber of neighboring areas. Topography of fontanelles. Cranial topography: projection onto the surface of the cranial vault of the middle artery of the meninges, upper sagittal sinus, major grooves and convolutions of the cerebral hemispheres.

The area of the mastoid process. Borders. External landmarks. Layers Vessels, nerves. The structure of the mastoid process. Shipo's trepanation triangle. The projection of the canal of the facial nerve, sigmoid sinus, tympanic cavity.

Base of skull. Anterior, middle and posterior cranial fossae, their contents. Topography of the cranial nerves. Shells of the brain, subshell spaces. Cerebrospinal fluid system. Sinuses of the dura mater and their connection with the superficial veins of the cranial vault and face. Typical fractures of the base of the skull during trauma. Surgical anatomy of congenital cerebral hernia and hydrocephalus. Front department. Borders. External landmarks. Division by area.

Mouth area. The structure of the upper and lower lips. The vestibule of the mouth, division into departments (upper and lower arch). Transitional fold of the mucosa and its significance. Surgical anatomy of congenital clefts of the upper lip and hard palate. Oral cavity: borders, soft and hard palate, layers, blood supply, innervation. Line "A", its meaning. Lymphatic ring Pirogov-Valdeira. Upper and lower jaw. Tooth structure, innervation, blood supply. Periodontium. Anatomical and clinical formulas of milk and permanent teeth. The concept of facial buttresses.

Tongue: structure, innervation, blood supply. Hyoid space, maxillofacial groove, its meaning. The bottom of the oral cavity: muscles, fascia, cellular spaces. Routes of spread of inflammatory processes from the oral cavity.

Nose area. Outer nose. Nasal cavity. The paranasal sinuses.

The area of the orbit. Borders, walls, departments, contents: muscles, vessels, nerves. The structural features of the orbit in children.

Buccal region. External landmarks. Borders, layers. Neurovascular formations. The projection of the exit of the infraorbital, infraorbital and chin branches of the trigeminal nerve from the bone canals. The topography of the buccal fat lump (Bisha) and its significance in the spread of the inflammatory process on the face.

Parotid chewing area. Borders. External landmarks. Under-maxillary fossa. Topography of the parotid gland in adults. Structural features of its fascial capsule. Cellular space of the parotid gland, its connection with the anterior periopharyngeal cellular space. Topography of blood vessels, nerves, duct of the parotid gland and their projection.

Deep area of the face. Borders. External landmarks. Temporal-maxillary-pterygoid and inter-wing-shaped cell fissures (according to N.I. Pirogov). The pterygoid venous plexus, its connection with the veins of the face and the sinuses of the dura mater. Topography of blood vessels and nerves. Peripharyngeal and post-pharyngeal cell spaces.

Superficial and deep lymph nodes. Venous and lymphatic outflow.

Surgical anatomy of congenital facial defects: coloboma, macrostomy, cleft upper lip and hard palate.

NECK

Borders. External landmarks. Division by area. Skeletonotomy, the projection of organs and neurovascular formations on the skin. Individual and age differences. Fascias and cell spaces. Ways of distribution of purulent processes. Reflexogenic zones. Superficial and deep lymph nodes of the neck. Inner triangle of the neck.

Sublingual region. Borders. Chin triangle: layers, vessels, nerves. The submandibular triangle. The bed and capsule of the submaxillary gland. Neurovascular formations and lymph nodes. Triangle N.I. Pirogov.

Carotid triangle, border. Common carotid artery, its bifurcation. External and internal carotid arteries. Sinocarotid zone. The relationship of the elements of the main neurovascular bundle of the neck. Topography of the sublingual, vagus, upper laryngeal nerves, sympathetic trunk, its nodes and cardiac nerves.

Sublingual region. Fascias and cell spaces. Topography of the thyroid and parathyroid glands, larynx, trachea, pharynx and esophagus. Syntopy of the lower thyroid artery and recurrent laryngeal nerve.

The sternocleidomastoid region. Borders. The projection onto the skin of the common carotid artery. Topography of the common carotid artery, vagus nerve, internal and external jugular veins. Stair-vertebral triangle: borders, layers. Topography of the subclavian artery and its branches, stellate node of the sympathetic trunk. Preclavicular space: subclavian vein, venous angle, thoracic lymphatic duct, phrenic nerve.

Areas of the lateral triangle. Muscle gaps. Topography of the subclavian artery and vein, brachial plexus, branches of the cervical plexus.

Surgical anatomy of congenital malformations: fistulas and cysts of the neck, torticollis.

CHEST

Borders. External landmarks. The projection of the organs of the chest cavity on the chest wall in adults and children. Individual and age-related differences in the shape of the chest and organs of the chest cavity.

Chest wall. Borders, areas. Layers Vessels and nerves. Superficial and deep cellular spaces. Topography of intercostal spaces. Internal thoracic artery, development of ribs, sternum, diaphragm. Funnel and keeled chest.

Topography of the mammary gland. Blood supply, innervation and lymphatic drainage from the mammary gland. Breast malformations: amastia, polymastia, gynecomastia.

Diaphragm, departments, legs. Features of its structure in children. Lumbo-rib triangle, holes and fissures. The ratio of the diaphragm to the organs of the chest and abdominal cavities.

Chest cavity. Pleural cavity. The projection of the borders of the pleura on the chest wall, pleural sinuses. Topography of the lungs. The division of the lungs into lobes and segments. Gate and root of the lung. Syntopy of neurovascular formations and bronchi, of the right and left roots of the lungs, their skeletonotomy.

Mediastinum. distribution, boundaries, division.

Anterior mediastinum. Thymus. Topography of the pericardium, heart, aortic arch and its branches, superior and inferior vena cava, brachiocephalic veins. Surgical anatomy of congenital heart and vascular defects: open ductus arteriosus, aortic coarctation, pulmonary stenosis, atrial and interventricular septal defects, tetralogy of Fallot. Topography of the trachea, phrenic, vagus and recurrent laryngeal nerves.

The posterior mediastinum. Topography of the thoracic aorta, unpaired and semi-unpaired veins, esophagus, vagus nerves, sympathetic trunk and its branches, thoracic lymphatic duct.

Anterior mediastinum. Thymus. Topography of the pericardium, heart, aortic arch and its branches, superior and inferior vena cava, brachiocephalic veins. Surgical anatomy of congenital heart and vascular defects: open ductus arteriosus, aortic coarctation, pulmonary stenosis, atrial and

interventricular septal defects, tetralogy of Fallot. Topography of the trachea, phrenic, vagus and recurrent laryngeal nerves.

The posterior mediastinum. Topography of the thoracic aorta, unpaired and semi-unpaired veins, esophagus, vagus nerves, sympathetic trunk and its branches, thoracic lymphatic duct.

Borders. External reference points, division into areas. The projection of the abdominal organs on the anterior lateral wall of the abdomen in adults and children. The structure of the anterior lateral wall of the abdomen in the medial and lateral sections. Blood supply, innervation, venous and lymphatic outflow. Portocaval and cavaval anastomoses. Weak spots. The structure of the white line of the abdomen, umbilical ring, lunar line. The inguinal canal in men, women. Inguinal triangle, inguinal space. Surgical anatomy of hernias of the white line of the abdomen, umbilical, external oblique, direct, sliding, congenital inguinal and femoral hernias. Postoperative hernia.

Topography of the inner surface of the anterior abdominal wall. Folds of the peritoneum. Pits, their relation to the internal opening of the inguinal canal. Congenital malformations of the anterior abdominal wall: navel fistula (urinary, vitelline), umbilical cord hernia.

ABDOMINAL CAVITY

Borders, the course of the peritoneum, its relation to the organs of the abdominal cavity. The division of the abdominal cavity into departments. Ligaments, bags, sinuses, canals, pockets, their clinical significance. Small oil seal, large oil seal.

Topography of the upper abdomen Abdominal food. Attitude to the peritoneum. Syntopy. Blood supply, innervation, lymphatic drainage.

Stomach. Attitude to the peritoneum, skeletotopy, syntopia, ligaments of the stomach. Blood supply, innervation, venous and lymphatic outflow. Topographic anatomy of the vagus nerves in the cardia and pylorus.

Duodenum. Departments, skeletotopy, attitude to the peritoneum, syntopy. Variants of the confluence of the common bile duct and pancreatic duct. Blood supply, innervation, venous and lymphatic outflow. Surgical anatomy of atresia and duodenal diverticulum.

Liver. Skeletotopy, attitude to the peritoneum. Syntopy. Shares, sectors, segments, ligaments of the liver. Syntopia of the elements of the hepatoduodenal ligament. Portal vein, portocaval anastomoses. Blood supply and innervation of the liver, lymphatic outflow.

Gall bladder. Attitude to the peritoneum, syntopy. Topography of the hepatic, cystic and common bile ducts, cystic artery. Triangle Kahlo. Surgical anatomy of atresia of the gallbladder, biliary tract.

Spleen. Skeletotopy, attitude to the peritoneum, ligaments. Syntopy. Blood supply, innervation, venous and lymphatic outflow.

Pancreas. Skeletotopy, attitude to the peritoneum, aorta, inferior vena cava and portal veins, celiac trunk and superior mesenteric artery, to the mesentery of the transverse colon. Pancreatic ducts. Blood supply, innervation, venous and lymphatic outflow. Surgical anatomy of the annular pancreas.

Topography of the lower abdomen.

Small intestine. Skeletotopy, syntopia, blood supply, innervation, lymph drainage. Methods for determining the onset of the small intestine. Surgical anatomy of congenital malformations, atresias, Meckel diverticulum, "doubling" of the intestinal tube.

Colon. Division into departments, relation to the peritoneum. Skeletotopy, syntopia. Ileocecal angle. Variants of the location of the cecum and vermiform appendix. The ratio of the appendix to the peritoneum. Blood supply, innervation, venous and lymphatic outflow. Features of blood supply to the small and large intestines. Surgical anatomy of congenital malformations: megacolon, Hirschsprung disease.

Lumbar region and retroperitoneal space

Lumbar region (posterior lateral wall of the abdomen). Borders. External landmarks. The projection of organs and large vessels on the skin. Layers, vessels, nerves and lymph formations. Weak spots. Bone

ligamentous apparatus of the lumbar spine. Individual and age features.

Retroperitoneal space. Borders, fascia and fiber layers. Ways of distribution of purulent streaks and hematomas. The projection of organs and blood vessels on the anterior and posterior walls of the abdominal cavity. The kidneys. Topography of the kidney gate. Options for the location of the elements of the renal pedicle. Options for the location of the elements of the renal pedicle. Surgical anatomy of congenital and acquired dystopia of the kidneys, horseshoe kidney.

Topography of the adrenal glands. Syntopia, blood supply, innervation, venous and lymphatic outflow.

Topography of the ureters. Syntopy of the departments, blood supply, innervation, lymph drainage. Projection on the anterior and posterior abdominal walls. Surgical anatomy of ureteral defects (congenital narrowing, valves, doubling, congenital hydronephrosis).

Topography of the abdominal aorta and its branches, inferior vena cava, nerve plexuses and sympathetic borderline trunk. Lymph nodes of retroperitoneal space. The formation of the thoracic lymphatic duct, unpaired and semi-unpaired veins.

SMALL PELVIS AND PERINEUM

Borders. External landmarks. The walls of the small pelvis and the bottom (pelvic diaphragm, urogenital diaphragm). Pelvic cavity. Bone-fibrous border of the entrance and exit of the small pelvis. Individual, sexual and age-related structural features of the pelvis. The division of the small pelvis into "floors": peritoneal, subperitoneal, subcutaneous.

The course of the peritoneum in men and women, the folds of the peritoneum. Bubble-rectal deepening in men, vesicoureteral and rectal-uterine deepening in women. Fascias, parietal and peritoneal cellular spaces of the pelvis. The course of the parietal and visceral leaves of the internal fascia of the pelvis and its spurs. Peritoneal-perineal aponeurosis (Denonville-Salishchev aponeurosis).

Lateral parietal cellular space. Topography of the internal iliac artery and its branches, sacral plexus and border sympathetic trunk, veins and venous plexuses. The connection of fiber of the subperitoneal floor of the pelvis with retroperitoneal space, fiber of the gluteal region, thigh and rectal-sciatic fossa.

Rectum. Division into departments, relation to the peritoneum. Topography of the rectum in men and women. Near rectal and posterior rectal cellular spaces. Blood supply, innervation, venous and lymphatic outflow. Features of the shape and position of the rectum, malformations of its development.

Bladder Attitude to the peritoneum, folds of the peritoneum. Bubble fascia. The pre-cystic, perivascular and peritoneal cell spaces. Syntopia of the bladder in men and women, its blood supply, innervation, lymphatic drainage. Features of the shape and position of the urinary bladder in children. Defects of the bladder (extrophy, diverticulum). Topography of the prostate gland, seminal vesicles, vas deferens.

Topography of the uterus and its appendages. Syntopy, ligaments. Blood supply, innervation, lymphatic drainage. Fibrous cellular spaces. Syntopia of the pelvic vagina, blood supply, innervation, lymph drainage. Features of the shape and position of the uterus and vagina.

Topography of the pelvic ureter, syntopy of their parietal and visceral parts. Crotch. Borders. Division by area. Anal triangle: layers, muscle lifting anus, its departments. External and internal sphincters of the rectum. Topography of the shameful neurovascular bundle. The cellular space of the sciatic-rectal fossa and its connection with the cellular spaces of the pelvis and gluteal region. Genitourinary triangle, superficial and deep layers, urogenital diaphragm. External genitalia in men: penis, scrotum and its contents, urethra. Surgical anatomy of defects of the external genitalia (undescended testicle, dropsy of the testicle and spermatic cord, epispadias, hypospadias). The external genitalia in women. Blood supply, innervation, lymphatic drainage.

3. Thematic plan for the distribution of hours by occupation

№	The name of the sections of the discipline	Total	Auditory lessons		SRS	Abr. technologies	Evaluation Tools
			Lectures	Practical class			
1.	1.1. Introduction to OSTA	150	30	45	75	LV, PL, MS, MG, WIRS, MPrez, C, RK, DI, RI, RM, B.	B, T, SZ, UIRS, R, O, MPrez, SRS.
	1.2. OSTA of the upper and lower limbs	48	8	15	25		
	1.3. Basic principles of amputation						
2.	Head, neck, chest. 2.1. Head OSTA 2.2 neck neck 2.3.chest of the breast	47	10	12	25		
3.	Abdomen and pelvis 3.1. OSTA of the abdominal wall and abdominal cavity 3.2. OSTA of the back and retroperitoneal space 3.3.OSTA of the pelvic organs	55	12	18	25		

4. Educational and methodological support of the discipline

I. Technical training aids:

The use of sectional (training) halls, museums, a bone room and a preparation room to familiarize students with natural (corpses and cadaveric material) and artificial materials. Tables, models, anatomical tools.

Multimedia complex (laptop, projector, screen), TV, video camera, slidescope, VCR, ideo and DVD players, monitors, multimedia presentations, tables. Sets of slides for various sections of the discipline. A set of tables for various sections of the discipline. Situational tasks, videos. Boards.

II. Training and information materials

Main literature:

1. Frank H. Netter, MD: Atlas of human anatomy 4th edition 2006
2. B. D Chaurasia Human anatomy upper limb and thorax, volume 1 2004
3. Tsyhykalo_o_v_topographical_anatomy_and_operative_surgery
4. Fominykh_t_a_ed_verchenko_i_a_topographic_anato

Additional literature:

1. B. D Chaurasia Human anatomy lower limb abdomen and pelvic, volume 2 2004
2. B. D Chaurasia Human anatomy head and neck, volume 3 2004

5. Evaluation Information

Assessment of students' knowledge is carried out according to a 100 point system as follows:

Rating (point)	Letter system	GPA digital equivalent	Traditional system
87 - 100	A	4.0	Fine
74 - 86	B	3.33	Good
	C		
61 - 73	D	2,33	Satisfactorily
	E	2.0	
31-60	Fx	0	Unsatisfactory
0-30	F	0	Traditional system

6. Scoring Policy

In accordance with the points accumulation card, a student can receive points for all types of classes. In lectures for active participation in the analysis of the topic of the lecture, in practical classes for active participation in the analysis of the topic of the lesson, for abstracts, drawing, etc. CPC for the preparation of schemes, tables, presentations. For foreign control - a maximum of 30 points, for the final control - a maximum of 40 points;

7. Course policy

The educational process is organized on the basis of a credit-modular system in accordance with the requirements of the Bologna process using a modular-rating system for assessing student performance using the AVN information system.

Students are presented with the following systems of requirements and rules of conduct in the classroom:

1. Obligatory attendance of classes;
2. Activity during classes;
3. Preparation for classes, homework and IWS;
4. Appearance for self-training;

Invalid:

- Delay and departure from classes
- Use of cell phones during class
- Deception and plagiarism
- Untimely delivery of tasks

The credit-modular system for organizing the educational process is based on the systematic work of students during the entire academic year. Types of training in human anatomy in accordance with the curriculum are:

1. Lectures;
2. Practical classes;
3. Independent work of students;
4. Individual work of choice

The topics of the lecture course reveal the problematic issues of the corresponding sections of human anatomy.

Practical exercises include mastery of:

- knowledge of Latin terminology;
- knowledge of the sources and patterns of embryonic development, the structure of organs and systems of human organs, clinical methods for their study (X-ray method, computed tomography, magnetic resonance imaging (MRI), ultrasound (ultrasound), endoscopy, etc.);
- skills of preparation, demonstration of anatomical formations on natural preparations, models, imitations;
- assessment of age, gender and individual characteristics of the structure of human organs;
- solving situational problems that have clinical anatomical justification.

Independent work involves the mastery of the ability:

- anthropometric (macroscopic) description of organs;
- to demonstrate organs, their parts and other formations on preparations;
- draw diagrams and drawings on the material of the topic;
- interpret the visualized results of clinical research methods (read radiographs, MRI, ultrasound, etc.);

Individual educational research (UIRS) or research (NIRS) student work (optional) involves:

- preparation of a review of scientific literature (abstract);
- preparation of illustrative material on the topics addressed (presentation, set of tables, diagrams and figures, etc.);
- participation in olympiads, etc.

Mastering the topic is monitored in practical exercises in accordance with specific goals. It is recommended to use the following forms of current control of students' training level:

- written (computer) testing in the amount of control work;
- ticket responses and situational tasks;
- control of practical skills of preparation and demonstration of anatomical preparations, followed by analysis and assessment of the structural features of human organs;
- analysis of topographic and anatomical relationships of human organs and systems (knowledge of the basics of clinical anatomy);

The final control of the assimilation of modules is carried out at their completion and includes:

- computer or written test control according to the volume of tests and situational tasks of control works;
- an oral interview on anatomical preparations (control of practical skills)

8. LIST OF QUESTIONS AND TASKS ON TOPICS AND FORMS OF CONTROL (current, milestone, final).

ARS Key Issues

General issues

1. Anomalies in the development of the vascular system
2. Variant anatomy of the lymphatic system
3. The relationship between blood vessels and fascia
4. Age bone changes
5. Congenital malformations of the heart and large vessels
6. Individual and typological characteristics of the size of the human spine
7. Clinical anthropology and physical status of a person
8. Integrated characteristics of organ topography
9. Extreme forms of individual variability of vessels and nerves
10. Blood supply and innervation of peripheral nerves
11. Morphology of human fat bodies
12. Moscow school of topographic anatomists
13. N.I. Pirogov and his role in the development of topographic anatomy and operative surgery
14. The main directions of development of topographic anatomy
15. Vascular and lymphatic malformations
16. The malformations of the musculoskeletal system
17. Genitourinary malformations
18. The Applied Importance of Fascia and Interfascial Cellular Spaces
19. Ways to spread purulent processes
20. Relief anatomy and determining the position of an object on the surface of the body
21. Human rudimentary organs
22. St. Petersburg school of topographical anatomists.
23. Teaching on the extreme forms of individual variability of organs and systems of the human body

24. Fetal topographic anatomy - applied and theoretical significance
25. Formation of somatic nerve plexuses
26. Build
27. Surgical anatomy of peripheral veins

Topographic anatomy and operative surgery of the limbs

29. Arthrotypology of human joints
30. External landmarks and projections of the main vessels and nerves of the upper limb
31. External landmarks and projections of the main vessels and nerves of the lower limb
32. Surgical anatomy of a dislocation of the hip joint
33. Laws of N.I. Pirogov on the relationship of blood vessels and fascia
34. Operational access to the vascular bundles of the limb
35. Hip
36. Topographic hip anatomy and operative surgery
37. Topographic anatomy and operative surgery of the lower leg
38. Topographic brush anatomy
39. Topographic anatomy and operative surgery of the subclavian and deltoid regions
40. Topographic anatomy and operative surgery of the popliteal fossa and knee joint
41. Topographic anatomy and operative surgery of the axillary and scapular regions
42. Topographic anatomy and operative surgery of the foot and ankle
43. Topographic anatomy and operative surgery of the gluteal region
44. Topography and operative surgery of the ulnar region and elbow joint
45. Topography and operative surgery of the shoulder
46. Topography and operative surgery of the main neurovascular bundles of the shoulder
47. Topography and operative surgery of the main neurovascular bundles of the forearm and hand
48. Topography and operative surgery of the shoulder joint
49. Topography and operative surgery of the forearm
50. Topography and operative surgery of vessels and nerves in various parts of the thigh
51. Topography and operative surgery of vessels and nerves in various parts of the lower leg

Topographic anatomy and head surgery

52. Anatomical features of the internal carotid arteries and arterial circle of the large brain
53. Variant anatomy of the ventricles of the brain
54. Intracranial topography. Krenlein-Bryusova scheme.
55. Extreme types of human skull base form.
56. Blood supply to the brain
57. The brain part of the head. Features of the topography of the soft parts of the head.
58. Subarachnoid space, ventricles of the brain, tanks
59. Malformations of the facial and brain skull.
60. Topographic anatomy and operative surgery of the facial section of the head
61. Topographic anatomy and operative surgery of the cranial vault
62. Topography and operative surgery of the brain
63. Topographic and anatomical relations of the structures of the temporomandibular joint
64. Surgical anatomy and operative surgery of the soft palate with congenital clefts of the upper lip and palate

Topographic anatomy and surgical neck surgery

65. Cellular spaces of the neck.
66. Topographic anatomy and operative surgery of the anterior neck
67. Topography of reflexogenic zones of the neck
68. Topography of the neurovascular bundles of the neck
69. Topography of the fascia of the neck

70. Topography of the neck. Triangles of the neck their practical meaning
71. Topography of the thyroid and parathyroid glands.
72. Surgical anatomy of the neck in the scapular-tracheal triangle

Topographic anatomy and operative surgery of the chest and chest organs

73. Variant anatomy of the thymus
74. Thoracic duct. Age features.
75. Features of the structure of the lymphoid formations of the respiratory system
76. Malformations of the chest and chest organs
77. Segmental lung anatomy: prehistory and history
78. Layers of the chest wall topography of the intercostal space
79. Topographic anatomy of the esophagus
80. Chest wall and chest cavity
81. Topographic anatomy of the diaphragm
82. Topographic anatomy and operative surgery of the lung
83. Topographic anatomy of the anterior mediastinum
84. Topographic anatomy of the posterior mediastinum
85. Topographic anatomy of the fetal heart and its large vessels
86. Topographic anatomy of childhood chest organs
87. Topography and operative surgery of the pleura, pleural sinuses
88. Topography and operative surgery of the heart. Features in children.
89. Topographic and anatomical justification of surgical access to the organs of the chest cavity
90. Surgical anatomy of the mammary gland

Topographic anatomy and operative surgery of the spine and spinal cord

91. Spinal canal and its contents
92. Spinal cord regeneration
93. Topographic anatomy and operative surgery of the spinal
94. Topographic anatomy and operative surgery of the spinal cord

Topographic anatomy and surgical abdominal surgery

95. Femoral hernia and groin anatomy
96. Options the structure of the anterior abdominal wall
97. Hepatoligament complex
98. Oblique inguinal hernia and its anatomy in men
99. Methods of revision of hollow organs
100. Hepatic bag. The concept of segmental structure of the liver
101. Malformations of the abdominal wall and organs of the abdominal cavity
102. Segmental structure of the liver and "anatomical" resection.
103. The structure of small and large human omentums
104. Human sphincter apparatus
105. Topographic anatomy of the duodenum and pancreas
106. Topographic anatomy of the femoral canal
107. Topographic anatomy and operative surgery of the stomach
108. Topographic anatomy and operative surgery of the abdominal organs.
109. Topographic anatomy and operative surgery of the liver and gall bladder
110. Topographic anatomy and operative surgery of the spleen
111. Topographic anatomy and operative surgery of the small intestine
112. Topography of the peritoneum: bags, ligaments, sinuses, pockets, channels of the abdominal cavity
113. Topography and mechanism of formation of hernias of the white line of the abdomen and umbilical ring

114. Topography of the inguinal canal. Surgical anatomy of an inguinal hernia
115. Topography of the anterolateral wall of the abdomen
116. Topography of the colon features of its blood supply
117. Topography of the appendix, options for its location
118. Surgical anatomy of femoral hernias.
119. Surgical anatomy of sliding hernias. Features of operations on them.
120. Surgical anatomy of the elements of the hepatoduodenal ligament of the liver

Topographic anatomy and operative surgery of the lumbar region and retroperitoneal space

121. Vegetative nerve plexuses of the retroperitoneal space
122. Lower hollow and portal veins
123. Genitourinary malformations
124. Topographic anatomy and operative surgery of retroperitoneal organs
125. Topographic anatomy and operative surgery of the lumbar region
126. Topography and operative surgery of the kidneys, adrenal glands and ureters
127. Topography of paired and unpaired branches of the abdominal aorta
128. Fasces and fiber layers of the retroperitoneal space

Topographic anatomy and pelvic surgery

129. Cellular spaces of the pelvis
130. Bone-ligamentous-muscular basis of the pelvis
131. Pelvic cavity
132. Topographic anatomy and operative surgery of the pelvic
133. Topography of the female perineum, its innervation. Methods of blockade of the reproductive nerves
134. Topography and operative surgery of the uterus and appendages
135. Topography and operative surgery of the bladder and urethra
136. Topography and operative surgery of the male perineum, its innervation
137. Topography and operative surgery of the rectum

